

nentech, and Medicis. She has also been an investigator for Centocor and Genentech.

Additional Information: This article was accepted for publication prior to January 18, 2008, the date the US Food and Drug Administration approved the use of adalimumab for the treatment of moderate to severe chronic plaque-type psoriasis in adults.

1. Graves JE, Nunley K, Heffernan MP. Off-label uses of biologics in dermatology: rituximab, omalizumab, infliximab, etanercept, adalimumab, efalizumab, and alefacept (part 2 of 2). *J Am Acad Dermatol*. 2007;56(1):e55-e79.
2. Boehncke WH, Prinz J, Gottlieb AB. Biologic therapies for psoriasis: a systematic review. *J Rheumatol*. 2006;33(7):1447-1451.
3. Baert F, Noman M, Vermeire S, et al. Influence of immunogenicity on the long-term efficacy of infliximab in Crohn's disease. *N Engl J Med*. 2003;348(7):601-608.
4. HUMIRA (adalimumab) [package insert]. North Chicago, IL: Abbott Laboratories; 2004.
5. Gordon KB, Langley RG, Leonardi C, et al. Clinical response to adalimumab treatment in patients with moderate to severe psoriasis: double-blind, randomized controlled trial and open-label extension study. *J Am Acad Dermatol*. 2006;55(4):598-606.

Whole-Body Cryotherapy in Atopic Dermatitis

Atopic dermatitis (AD) is a chronic inflammatory skin disease with dry and itchy skin causing remarkable adverse impact on quality of life. Some patients do not tolerate treatments, or in some cases the treatments are ineffective. Effective combination therapies for moderate or severe AD are lacking or scarce. Very cold air has been reported to increase the body's antioxidative capacity. The cold has also been shown to reduce the conduction velocity of peripheral nerves¹ and the nerve ganglia capacity to synthesize acetylcholine,² which is considered a neurotransmitter in atopic pruritus.³ People who regularly swim in ice-cold water have increased concentrations of anti-inflammatory cytokines in their peripheral blood. Thus, cold air or water is suggested to have local and systemic anti-inflammatory effect and also to relieve itch.

Locally applied cryotherapy has been used in experimental treatments of inflammatory and substantially itching skin diseases such as psoriasis and prurigo nodularis. Whole-body cryotherapy has been developed and used in treating rheumatic inflammation and pain since the 1970s.⁴ In a cryotherapy chamber, the whole body is exposed to temperatures between -100°C and -180°C . The rationale for this study was to assess the effect of whole-body cryotherapy on the signs and symptoms of AD.

Methods. Eighteen healthy adults (10 men and 8 women) with mild to moderate AD were enrolled (the criteria of Rajka and Langeland⁵). Patients with cardiovascular disease, uncontrolled asthma, other remarkable skin diseases, or cold urticaria were excluded. The participants gave written informed consent. The study was approved by the scientific ethics committee for Helsinki University Hospital.

Topical anti-inflammatory preparations (ie, corticosteroids or topical calcineurin inhibitors [TCIs]) or systemic antihistamines were not allowed for 1 week before or at any time during the study. The washout period for systemic therapy and phototherapy was 6 weeks. Whole-body cryotherapy was given 3 times a week for 4 weeks in Haikko Spa

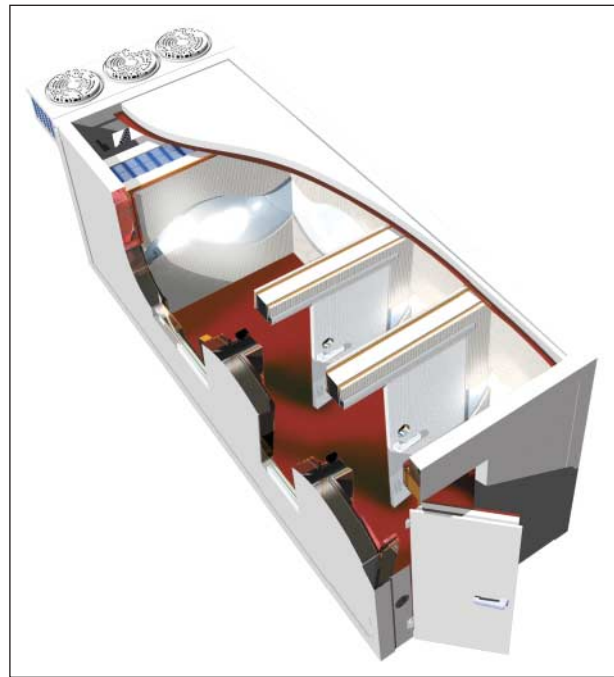

Figure 1. Sketch of the Uniers Cryo-Combi whole-body cryotherapy device (Oy MJG Uniers Ab, Helsinki, Finland) showing the 3 chambers.

and Rehabilitation Center, Porvoo, Finland, followed by an 8-week follow-up period. The whole-body cryotherapy device (Uniers Cryo-Combi; Oy MJG Uniers Ab, Helsinki, Finland) consists of 3 chambers set at different temperatures (**Figure 1**). The first 2 chambers are meant for pre-cooling (-30°C and -60°C), and the patient remains in these for a very short time. The third chamber temperature reaches -110°C , and the patient remains inside for 1 to 3 minutes wearing a bathing suit or trunks, acral parts covered.

The primary end point was the change in the Scoring of Atopic Dermatitis index (SCORAD) (scale, 0-103) during the treatment period. Secondary end points included changes in transepidermal water loss (TEWL) measured by Vapometer (Delfin Technologies Oy, Kuopio, Finland) and self-assessed visual analog scale (VAS) (0-100) for pruritus and sleep disturbances. Changes in quality of life were assessed with the Dermatology Life Quality Index (DLQI). The main outcome measures were based on assessments made before and after the treatment period. The SCORAD evaluations were performed weekly during the treatment period and every 2 weeks thereafter.

Statistical analysis was performed with SPSS 13.01 for Windows (SPSS Inc, Chicago, Illinois) using the Wilcoxon signed rank nonparametric test. *P* values less than .05 were regarded as significant. The patient data were evaluated on intention-to-treat and last-observation-carried-forward bases.

Results. Sixteen of 18 patients completed the treatment period. On average, 11 treatment sessions were completed (range, 9-12); omitted sessions could not be substituted. Of the patients who left the study, 1 patient discontinued owing to worsening dermatitis, the other owing to work schedule. The mean SCORAD index decreased from 38.7 to 31.1 (-19.6%) ($P = .03$). The mean TEWL improved from $58.8 \text{ g/m}^2/\text{h}$ to $47.4 \text{ g/m}^2/\text{h}$ (-19.4%) ($P = .03$).

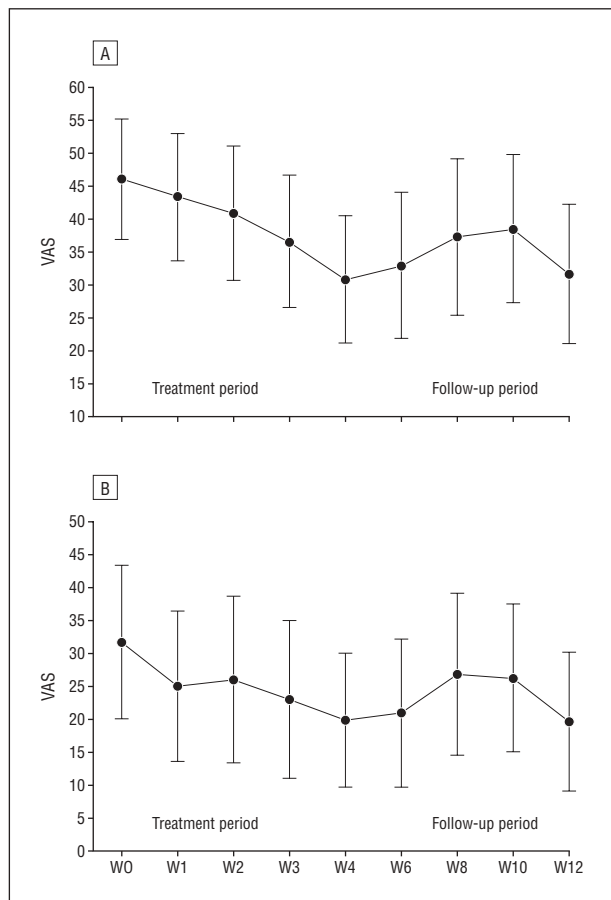


Figure 2. Visual analog scales (VAS) for itch (A) and sleep loss (B) at weeks (W) 0 to 12. Error bars indicate 95% confidence intervals.

The mean VAS for sleep loss decreased from 32 to 20 (-37.5%) ($P=.047$) and for pruritus from 46 to 31 (-32.6%) ($P=.02$). The treatment effect was observed from the third week onward, and it did not reach plateau during the treatment period (**Figure 2**). The mean DLQI decreased from 5.27 to 5.00 ($P=.40$).

In those patients who completed both the treatment and the follow-up periods ($n=8$), the SCORAD index continued to decrease after the treatment period. The therapy was more effective during the treatment period in women vs men (SCORAD, -24.3% vs -16.0% ; TEWL, -26.1% vs -13.3%). Three patients had treatment-related adverse events, all mild acral frostbite. The most common reasons for discontinuing the follow-up period were worsening of dermatitis requiring topical steroids or TCIs (5 patients) and loss to follow-up (3 patients). All but 2 patients experienced the therapy as “somewhat cold” to “extremely cold” (5-point scale from cold to extremely cold), but the treatment as a whole was regarded as pleasant, and all were willing to undergo further treatment courses.

Comment. Phototherapy has been used as the second-line therapy for atopic dermatitis resistant to topical corticosteroids. The problem with UV therapy is its carcinogenicity in long-term treatment, and the risk may be even higher if multiple courses precede the use of TCIs and cy-

closporine. Whole-body cryotherapy, another physical therapy, offers a new option in the armament of therapies for atopic dermatitis. In our patients, whole-body cryotherapy was successfully carried out as monotherapy during the treatment period, ie, no anti-inflammatory topical preparations were used. Thus, it clearly has a steroid-sparing effect with additional statistically and clinically significant improvements in pruritus and sleep disturbances. The findings are in agreement with statistically significant changes in SCORAD and TEWL. The tendencies of SCORAD (data not shown), pruritus, and sleep loss to continue improving even after the treatment period suggests that the ultimate treatment effect was not attained during the 4-week treatment period. Future studies with a higher number of treatment sessions comparable to phototherapy are thus indicated.

The compliance of our patients was very good. Although they experienced the treatment as very cold, all of them would have been willing to continue the therapy after the study. Compared with phototherapy, the mode of action and safety of whole-body cryotherapy⁶ may offer advantages when combined with other treatment methods such as TCIs and cyclosporine.

Adverse effects in our patients were very few. Theoretically, no increased risk of malignancy is expected. To our knowledge, the whole-body cryotherapy device used in the present study is the first to use both liquid nitrogen and compressor technology to produce the cold air. Thus, an optimal oxygen level (22%) is achieved in the chamber that allows even patients with asthma to undergo the treatment.

Taras Klimenko, MD
Siru Ahvenainen, RN
Seija-Liisa Karvonen, MD, PhD

Correspondence: Dr Karvonen, Skin and Allergy Hospital, Meilahdentie 2, PO Box 160, FIN-00029 Huch, Finland (seija-liisa.karvonen@helsinki.fi).

Author Contributions: Drs Klimenko and Karvonen had full access to all the data in the study and take responsibility for the integrity of the data and the accuracy of the data analysis. *Study concept and design:* Klimenko and Karvonen. *Acquisition of data:* Klimenko and Ahvenainen. *Analysis and interpretation of data:* Klimenko and Karvonen. *Drafting of the manuscript:* Klimenko and Karvonen. *Critical revision of the manuscript for important intellectual content:* Klimenko, Ahvenainen, and Karvonen. *Statistical analysis:* Klimenko. *Obtained funding:* Klimenko and Karvonen. *Administrative, technical, and material support:* Klimenko and Karvonen. *Study supervision:* Klimenko and Karvonen.

Financial Disclosure: None reported.

Funding/Support: The design and conduct of the study and collection, management, analysis, and interpretation of the data were supported by grants from The Finnish Society of Dermatology and The Finnish Society of Dermatopathology (Drs Klimenko and Karvonen).

1. Franz DN, Iggo A. Conduction failure in myelinated and non-myelinated axons at low temperatures. *J Physiol.* 1968;199(2):319-345.
2. Kostial K, Vouk VB. The influence of temperatures on the acetylcholine output from a sympathetic ganglion. *J Physiol.* 1956;132(1):239-241.
3. Heyer GR, Hornstein OP. Recent studies of cutaneous nociception in atopic and non-atopic subjects. *J Dermatol.* 1999;26(2):77-86.

4. Yamauchi T. Whole body cryotherapy is a method of extreme cold -175°C treatment initially used for rheumatoid arthritis. *Z Phys Med Baln Med Klim.* 1986;15:311.
5. Rajka G, Langeland T. Grading of the severity of atopic dermatitis. *Acta Derm Venereol.* 1989;144(suppl):13-14.
6. Westerlund T, Oksa J, Smolander J, Mikkelsen M. Thermal responses during and after whole-body cryotherapy (-110°C). *J Therm Biol.* 2003;28:601-608.

VIGNETTES

A Complication of Mesotherapy: Noninfectious Granulomatous Panniculitis

Mesotherapy can be associated with noninfectious granulomatous panniculitis and consequent scarring.

Report of a Case. A 37-year-old white woman was referred for consultation for a 5-month history of panniculitis involving her buttocks and lower extremities corresponding to the sites of previous mesotherapy injections

for “cellulite.” Six months prior to presentation, the patient had undergone a series of 3 separate mesotherapy injection sessions at the home office of a licensed practical nurse. The patient stated that deoxycholate was a component of the injection solution. Beginning approximately 1 month following the injections, she noted “lumps” under her skin, which gradually enlarged, were tender and red, then discharged a yellow fluid, and finally healed leaving scars. She developed these lesions in each of the areas treated with mesotherapy injections.

On examination of the buttocks; posterior, lateral, and medial aspects of the thighs; superior and medial aspects of the knees; and medial aspects of the lower legs, numerous violaceous tender nodules with and without crusted erosions were noted along with hyperpigmented macules (**Figure 1**). She denied any systemic symptoms.

Specimens from repeated biopsies showed deep dermal and pannicular inflammation and mixed granulomatous inflammation with fibrosis (**Figure 2**), and multiple stains for microorganisms proved negative. Findings

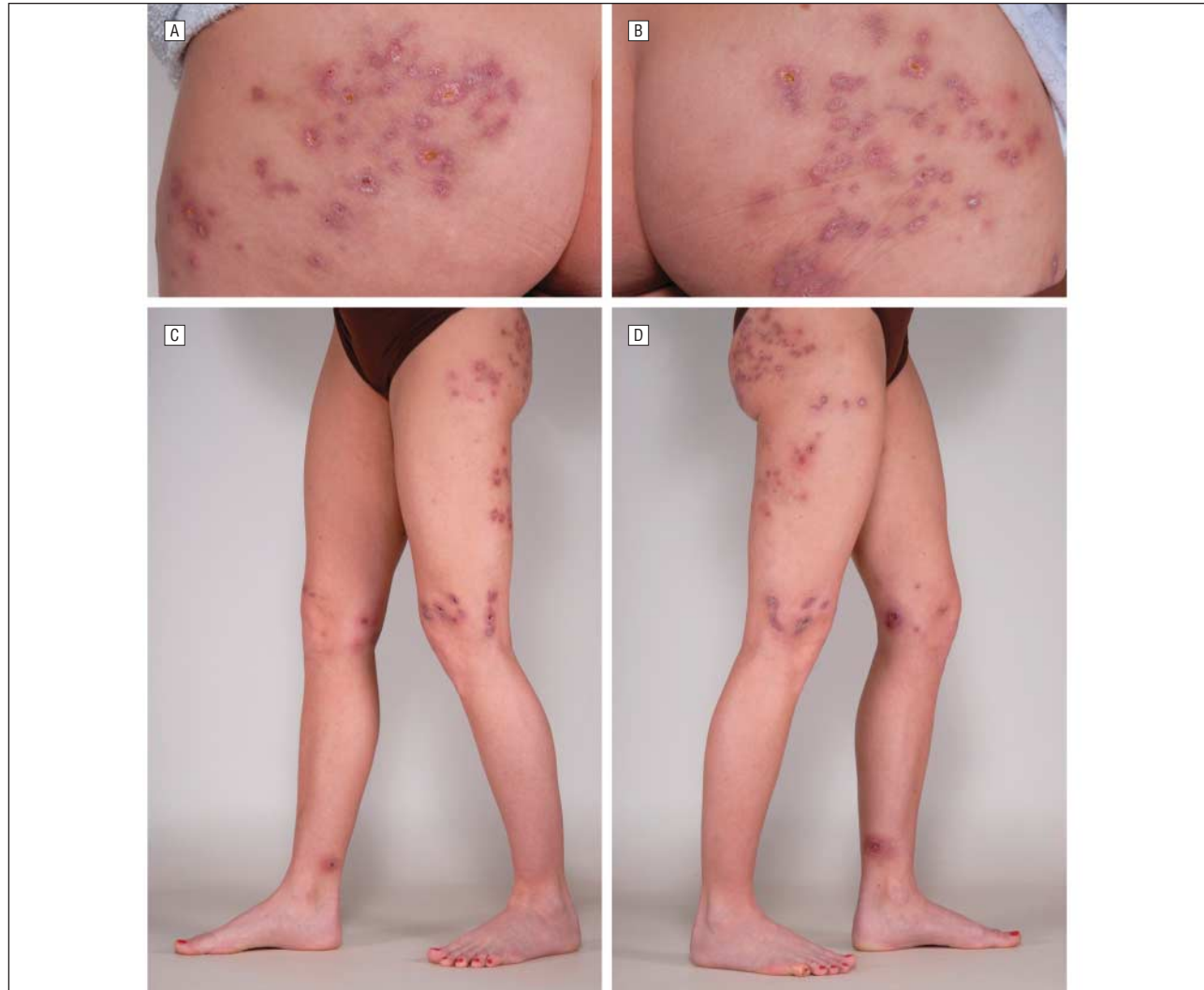


Figure 1. Numerous violaceous nodules, with and without crusted erosions, and hyperpigmented macules at injection sites. A, Left buttock; B, right buttock; C, left thigh, left lateral and superior aspects of the knee, right medial aspect of the knee, and right medial aspect of the lower leg; and D, right thigh, right lateral and superior aspects of the knee, left medial aspect of the knee, and left medial aspect of the lower leg.